BIOTECK®

The science of bone tissue

Managing a vestibular infra-bony periodontal defect in the aesthetic zone through bone regeneration: a case report.

Alberto Materni

DDS, Private Practice, Genova, Italy

OSTEOXENON® by BIOACTIVA®

Short summary

Management of a vestibular infra-bony periodontal defect through grafting enzymatic-deantigenic equine bone substitutes is presented. An infra-bony defect was diagnosed on vestibular side at position 2.3, showing oedema of soft tissues. Probing revealed the presence of a 7-8 mm pocket. After granulation tissue debridement the defect was grafted with an enzyme-deantigenic, collagen preserved, bone substitute in gel form, and covered with an equine pericardium membrane. Post-operative control at 90 days showed a probing depth of 1-2 mm, and a complete recovery of papillae health, with no gingival recession. These results suggest that even in the presence of a bone defect featuring only one wall, enzyme-deantigenic, collagenic bone substitutes could effectively prompt bone regeneration, providing a good gingival health and a satisfying aesthetic outcome.

Keywords:

periodontal defect, bone substitutes, bone regeneration

Abstract

Objective. **Vestibular-only, infra-bony defects in the aesthetic zone represent a challenging condition for bone regeneration. The aim of the present report is to present a case where, grafting enzymatic-deantigenic, collagen preserved, bone substitutes, it was possible to reduce infra-bony pocket depth, recovering gingival heath and obtaining a good aesthetic outcome.**

Methods**. A patient presented with an infra-bony defect on the vestibular side at position 2.3. Initial probing depth was 7-8 mm. Even if only one bone wall could provide blood supply, bone regeneration had to be attempted in order to diminish the risk of an aesthetic failure. After debridement of granulation tissue, the defect was grafted with an enzyme-deantigenic, collagen preserved, equine-derived bone substitutes, and covered with an equine pericardium membrane. Controls followed at 14, 30, 45 and 90 days after surgery.**

Results. **The healing of soft tissues continued until complete recovery at 90 days, showing no gingival recession. Probing depth, still at 90 days, was only 1-2 mm.** ***Conclusions.*** **The way we managed this challenging infra-bony defect has allowed to give a good recover of gingival health and a satisfying aesthetic outcome. These results suggest that enzyme-deantigenic, collagen preserved, bone substitutes could be used successfully even in the presence of particularly challenging infra-bony defects.**

Introduction

Chronic periodontitis (CP) is a destructive disorder affecting 10 to 30% of the world-wide population[1-3] caused by the bacteria within plaque. Infection stimulates inflammation of periodontal tissues eventually resulting in a disruption of both connective and bone tissues around the tooth root. This leads to a formation of a periodontal pocket which further acts as a bacteria reservoir, leading to a chronic and progressively destructive disorder. Beyond common inflammation symptoms (as pain and swelling) the patient may suffer from teeth loosening, aesthetic problems, abscess formation and eventual tooth loss.[4] Treatment focuses on blocking the condition by debriding the periodontal pocket by scaling techniques and, if needed, through periodontal surgery. Periodontal defects may be classified according their morphology and other criteria into different classes. Infra-bony defects are one of the most represented and appear as crater-like defects around the root, when the base of the pocket is apical to the crest of the alveolar bone. They present major challenges: spontaneous healing, in fact, is not followed by formation of new supporting tissue[5]. Treatment of deep defects may still result in residual pockets which are a risk factor for further deterioration[6]. Moreover, conventional surgery tends to increase gum recession, which can cause aesthetic problems. This has led to develop surgical techniques aimed to regenerate the lost tissues. GTR (Guided Tissue Regeneration) procedures (a biocompatible barrier membrane, either resorbable or non-resorbable, is surgically implanted to cover and protect the bone defect) guide the formation of new tissues by preventing the migration of epithelial cells into the bone defect, allowing time for teeth supporting tissues to heal. Additional bone grafting can lead to a better outcome, allowing to restore the entire bone volume lost because of the disease.

Introduction

Among bone grafts materials, bovine deproteinized bone as allowed to achieve satisfying results[7-9] in the treatment of infra-bony defects. Though, even if deproteinized bovine bone has shown good osteoconductive properties still it may also have a low resorption capacity[10]. An alternative xenograft is an enzymatically deantigenated form of equine bone. The enzymatic process used to clean this material preserves type I bone collagen component in its native, non-denatured, state, and this should allow an improved bone-regeneration process, given the well-known biological properties of this molecule[11-18].

Actually, when osteoclasts were cultured over such equine, enzymatically deantigenated and collagen-preserving bone substitutes[19], their adhesion and activity was significantly higher than that found for osteoclasts grown over deproteinized bovine bone[20]. Moreover, when sites augmented with equine bone alone were compared to others augmented with the same material added with autogenous bone, immunohistochemical tests showed no differences between the two as far as the expression of some biochemical markers of bone regeneration were concerned[21].

Enzyme-deantigenic equine bone has already been used in clinical practice as a scaffold in bone regeneration of different bone defects[22-27], and has also been applied in orthopaedic regenerative surgery[28]. It has also been recently used to treat cases where implant threads exposure resulted from positioning[29].

To our knowledge, no cases of infra-bony defect treatment with such bone substitutes have been reported thus far in literature. The aim of this study, therefore, is to present how a severe infra-bony defect was treated by grafting an enzyme-deantigenic, equine bone graft after proper defect debridement.

Materials and methods

A no-smoker 75 year-old man with no past medical history presented complaining pain in correspondence of the canine, at position 2.3. After oral hygiene, visit followed showing oedema and change in color at the 2.3 position itself. Probing showed, only on the vestibular side, a deep (7-8 mm) pocket(Fig. 1a-b). Intraoral X-ray was not able to show the defect because of the narrow shape of the palate, and the consequent juxtaposition of element 2.4 (Fig. 2a-b). A infra-bony defect was diagnosed and a procedure, calling for debridement, deep scaling, root planing and bone regeneration of the defect was planned. The patient gave his informed consent.

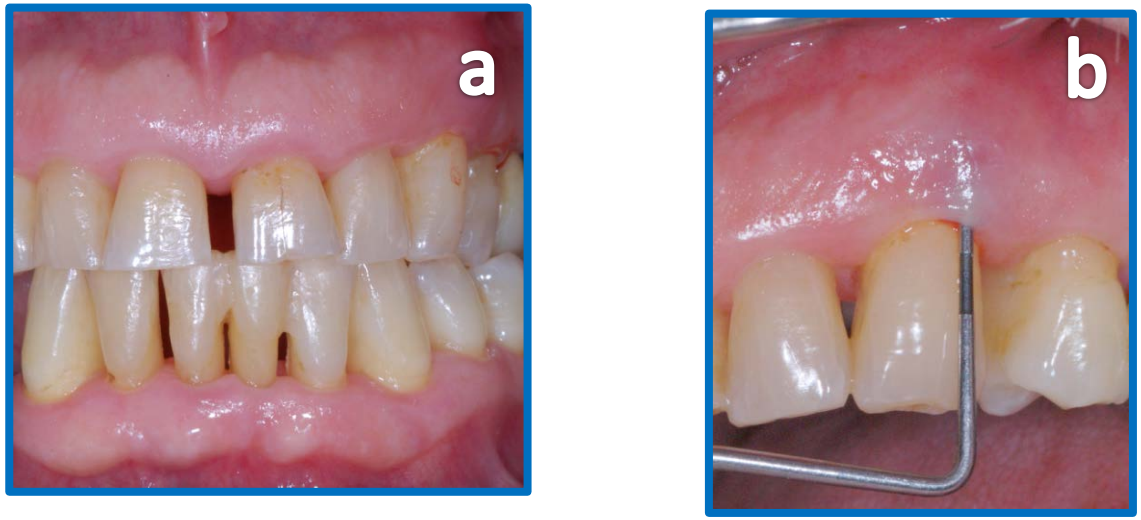

Fig. 1. A) Pre-surgical view. Oedema and change in color at 2.3 position. B) probing depth is 7-8 mm

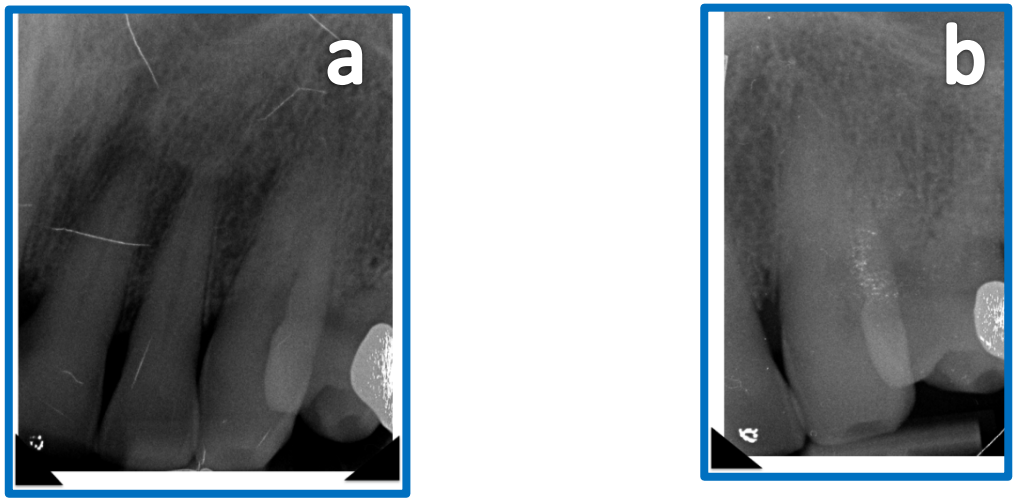

Fig. 2. A) Intraoral X-rays at positions 2.1, 2.2, 2.3 and 2.4. The juxtaposition of element 2.4 (B) doesn't allow to detect the defect at 2.3 position.

Materials and methods

Antibiotic prophylaxis (Amoxicillin/Clavulanic acid, Augmentin, Glaxo-SmithKline, Verona, Italy), 2 g, 1 hour before surgery and then 1 g every 12 hours for 5 days, was initiated and the patient was subjected to a mouth rinse with Chlorhexidine 0.2% (Corsodyl, Glaxo-SmithKline, Verona, Italy) for one minute, and instructed to perform mouth rinses with Chlorhexidine 0.12% (Corsodyl, Glaxo-SmithKline, Verona, Italy) on the following days. Local anaesthetic was administered by means of an infiltration with 1% Articaine with Adrenaline 1:100000.

Materials and methods

A full-thickness mucoperiosteal flap was detached preserving papillae (according to the simplified papilla preservation technique). Papillae were dislocated on the vestibular side in order to expose the underlying tissue (Fig 3a-b). Some dark tartar could be also observed. The granulation tissue was debrided by deep scaling with ultrasonic burs (Sirosonic TL Intstrument 4L, Siroperio PE 1, Sirona, USA) and manual curettes (AE G 5-6 XP X; AE G 7-8 XP X; American Eagle Instruments Inc., Missoula, USA) and root planning with slow speed rotating instruments (Perioset 15micron, Intensiv SA, Montagnola, Switzerland) were performed in order to get a clean, smooth dental surface (Fig. 4).

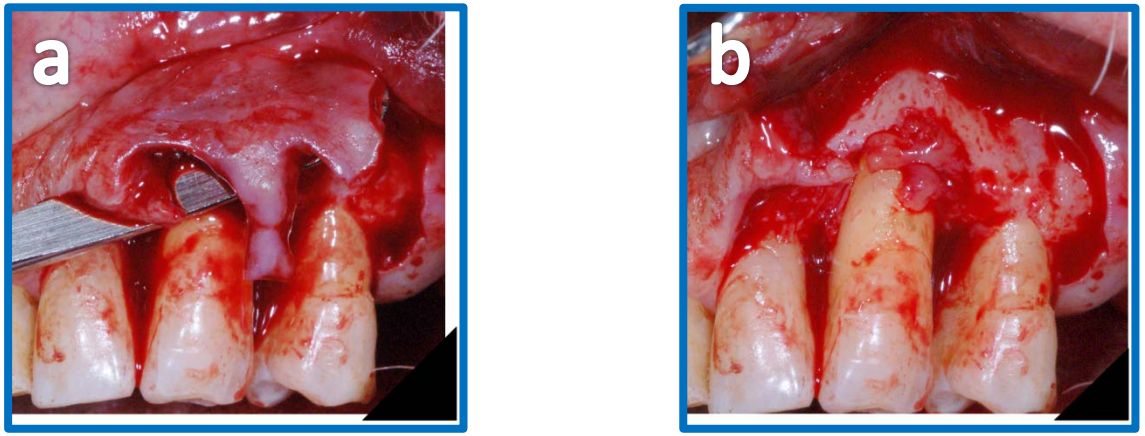

Fig. 3. Papillae were dislocated on the vestibular side (A) in order to expose the underlying tissue (B).

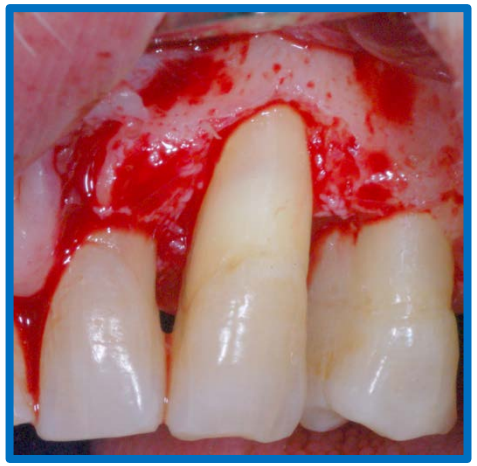

Fig. 4. The dental surface was cleaned and the granulation tissue debrided.

Materials and methods

The defect was grafted with a 1:1 cancellous-cortical mixture of enzyme-deantigenic equine granules in gel form (Osteoplant Osteoxenon Mix Gel, OX21 - Bioteck, Vicenza, Italy) and covered with an equine pericardium membrane (Heart Pericardium Membrane – HRT-001, Bioteck, Vicenza, Italy) (Fig. 5a-b). The membrane was fixed apically, on the vestibular side, with two titanium pins. Then it was shaped in order to make it pass through the interproximal spaces, the bone peaks supporting it, and covered with the papillae which were repositioned in their original location. The aim of such procedure was to give further stabilization to the particles grafted. The two ends of the membrane were sutured with a resorbable thread (Vicryl 5-0, Ethicon, Inc., Johnson & Johnson company, USA). Flap suture followed (Cytoplast PTFE Suture 3-0, Osteogenics Biomedical, Lubbock, USA) (Fig. 6-7). Occlusal load at 2.3 was diminished in order to reduce micro-movements possibly affecting guided tissue regeneration processes.

Ketoprofen 100 mg (Ibifen 100 mg, IBI-Lorenzini, Aprilia, Italy) was prescribed every 12 hours for 3 days. The patient was recalled after 14 days for suture removal, and controls followed at 30, 45 and 90 days after surgery.


OSTEOXENON®
by BIOACTIVA®
OX

OSTEOXENON

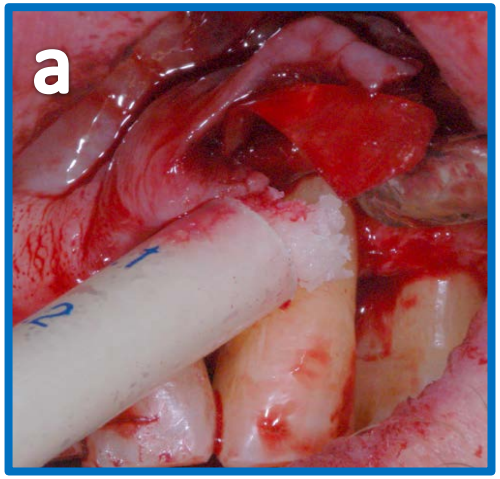

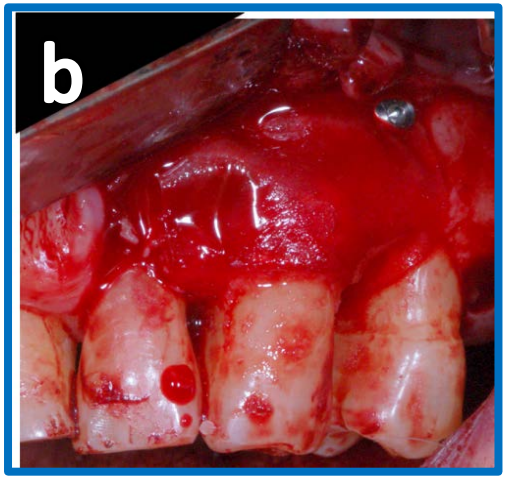

Fig. 5. The defect was grafted with enzyme-deantigenic equine granules in gel form (A) and covered with an equine pericardium membrane (B).

Fig. 6. The flap is sutured maintaining papillae below the area treated by GTR.

Fig. 7. Element 2.3 is slightly unloaded in order to avoid micro movements which could interfere with tissue regeneration.

OSTEOXENON

Results

Immediate post-operative course was uneventful. At 14 days, the patient presented only a slight edema at the papillae that disappeared at the following control (Fig. 8a-b-c). At 1 month control, soft tissues showed no inflammation, papillae had undergone re-epithelization and were still undergoing healing (Fig. 8c). Even if undergoing slight contraction, further healing was observed at 45 days (Fig.9). First control probing was performed at 90 days, and probing depth was 1-2 mm only (Fig. 10a-b). No bleeding was observed. At 90 days, papillae had completely recovered their healthy, pink appearance, and no oedema could be observed.

Fig. 8. A) A slight oedema is present at the papillae at 14 days after the surgery. B) At 30 days papillae are pink and re-epithelization is undergoing. C) Panoramic view at 30 days after the surgery: healing is undergoing.

Fig.9. At 45 days after surgery papillae are undergoing further healing.

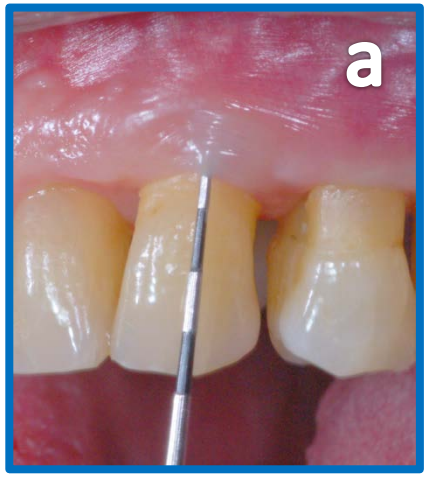

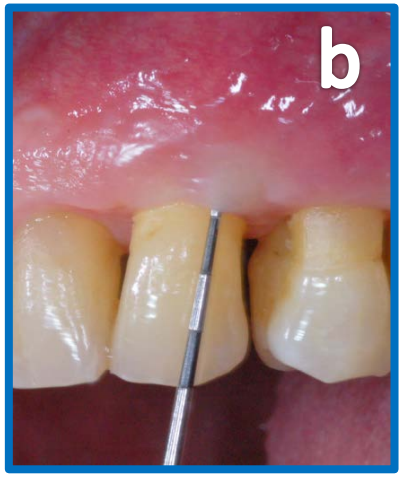

Fig. 10. Probing control at 90 days post-surgery. Papillae had completely recovered healthy appearance and no bleeding was observed (A). The probe stopped at 1-2 mm depth (B).

Discussion

Given the initial condition, we deem the results of this clinical case quite satisfying. Usually infra-bony defects being treated feature 3 or at least 2 walls, in order to exploit their partial containing shape, and bone regeneration is performed in the interproximal spaces to allow better granules stabilization. This patient, instead, presented a one-wall only, totally vestibular bone defect. Such a condition is quite challenging for bone regeneration to develop properly since blood vessels can spring from one bone wall only, diminishing the probability of effective vessel and cell colonization of the graft. Moreover, the defect, not being between two teeth, was totally unprotected and graft stabilization was much more difficult.

Though risk of recession was quite high and regeneration had to be attempted anyway, in order to diminish the risk of an aesthetic failure.

Discussion

It is unknown if bone and, above all, periodontal ligament regeneration occurred, since a second look was not possible. Though, an infra-bony pocket – when treated through deep scaling and root planing, even if healed, usually shows a long epithelial attachment for nearly half of its length while the remaining length shows recession (this condition is regarded as healing, even if not as a *restitutio ad integrum*). On the contrary we did not observe any recession at all and probing depth was reduced to a minimum, possibly suggesting a real alveolar bone and periodontal ligament healing.

Discussion

Supposing bone regeneration had really occurred, this could have been prompted by the particular bone substitute we grafted. Bone regeneration, in fact, could have possibly been facilitated by the presence of bone collagen in its native, non-denatured form, confirming what was already observed in previous *in vitro*[19] and clinical studies where histological and histomorphometric analyses were performed[21,22,25,27].

Conclusions

The present case shows how a vestibular-only infra-bony defect in the aesthetic zone was successfully treated by deep scaling and root planing, and grafting an enzyme-deantigenic equine bone substitute, featuring bone collagen preserved. Our results show a quite good recover of gingival health and a real satisfying aesthetic outcome. Probing depth reduced to no more than 2 mm and no gingival recession was observed. Our result suggests that enzyme-deantigenic, collagenic bone substitutes could be used successfully to treat even challenging infra-bony defects.

References

1. Baelum V, Fejerskov O, Karring T. Oral hygiene, gingivitis and periodontal breakdown in adult Tanzanians. Journal of Periodontal Research 1986;21(3):221–32.

2. Löe H, Anerud A, Boysen H, Morrison E. The natural history of periodontal disease in man. Rapid, moderate and no loss of attachment in Sri Lankan labourers 14 to 46 years of age. Journal of Clinical Periodontology 1986;13(5): 431–45.

3. Oliver R, Brown L, Loe H. Variations in the prevalence and extent of periodontitis. Journal of the American Dental Association 1991;122(6):43–8.

4. Needleman I,Worthington HV, Giedrys-Leeper E, Tucker R. Guided tissue regeneration for periodontal infra-bony defects. Cochrane Database of Systematic Reviews 2006, Issue 2 (reviewed 2012).

5. Caton J, Zander HA. Osseous repair of an infrabony pocket without new attachment of connective tissue. Journal of Clinical Periodontology 1976;3(1):54–8.

6. Claffey N, Nylund K, Kinger T, Garret S, Egelberg J. Diagnostic predictability of scores of plaque, bleeding, suppuration and probing depth for probing attachment loss. Journal of Clinical Periodontology 1990;17(2):108–14.

7. Baldini N, De Sanctis M, Ferrari M. Deproteinized bovine bone in periodontal and implant surgery.Dent Mater. 2011 Jan;27(1):61-70

8. Silvestri M, Rasperini G, Milani S. 120 infrabony defects treated with regenerative therapy: long-term results.J Periodontol. 2011 May;82(5):668-75

9. Gokhale ST, Dwarakanath CD. The use of a natural osteoconductive porous bone mineral (Bio-Oss™) in infrabony periodontal defects. J Indian Soc Periodontol. 2012 Apr;16(2):247-52.

10. Zitzmann NU, Scharer P, Marinello CP, Schupbach P, Berglundh T. Alveolar ridge augmentation with Bio-Oss: a histologic study in humans. Int J Periodontics Restotorative Dent 2001;21:288-295

11. Baslé MF, Lesourd M, Grizon F, Pascaretti C, Chappard D. Type I collagen in xenogenic bone material regulates attachment and spreading of osteoblasts over the beta1 integrin subunit. Orthopade 1998 Feb;27(2):136-142.

OSTEOXENON®

References

12.Green J, Schotland S, Stauber DJ, Kleeman CR, Clemens TL. Cell-matrix interaction in bone: type I collagen modulates signal transduction in osteoblast-like cells. Am J Physiol 1995;268(5 Pt 1):C1090-103.

13. Mizuno M, Fujisawa R, Kuboki Y. Type I collagen-induced osteoblastic differentiation of bone-marrow cells mediated by collagen-alpha2beta1 integrin interaction. J Cell Physiol 2000 Aug;184(2):207-213.

14. Liu G, Hu YY, Zhao JN, Wu SJ, Xiong Z, Lu R. Effect of type I collagen on the adhesion, proliferation, and osteoblastic gene expression of bone marrow-derived mesenchymal stem cells. Chin J Traumatol 2004;7(6):358-362.

15. Gungormus M, Kaya O. Evaluation of the effect of heterologous type I collagen on healing of bone defects. J Oral Maxillofac Surg 2002;60(5):541-545.

16. Gungormus M. The effect on osteogenesis of type I collagen applied to experimental bone defects. Dent Traumatol 2004;20(6):334-337.

17. Regazzoni C, Winterhalter KH, Rohrer L. Type I collagen induces expression of bone morphogenetic protein receptor type II. Biochem Biophys Res Commun 2001;283(2):316-322.

18. Toroian D, Lim JE, Price PA. The size exclusion characteristics of type I collagen: implications for the role of noncollagenous bone constituents in mineralization. J Biol Chem 2007;282(31):22437-22447.

19. Perrotti V, Nicholls B, Piattelli A. Human osteclast formation and activity on an equine spongy bone substitute. Clin Oral Impl Res 2009;20(1):17-23.

20. Perrotti V, Nicholls BM, Horton MA, Piattelli A. Human osteoclast formation and activity on a xenogenous bone mineral. J Biomed Mater Res A 2009;90(1):238-246.

21. Artese L, Piattelli A, Di Stefano DA, et al. Sinus lift with autologous bone alone or in addition to equine bone: an immunohistochemical study in man. Implant Dent 2011;20(5):383-388.

22. Di Stefano DA, Artese L, Iezzi G, et al. Alveolar ridge regeneration with equine spongy bone: a clinical, histological, and immunohistochemical case series. Clin Implant Dent Relat Res 2009;11(2):90-100

23. Pistilli R, Checchi V, Iezzi G, Nisii A, Pecora CN, Felice P. Incremento di un mascellare superiore atrofico con innesti a blocco di osso eterologo di origine equina per riabilitazione con protesi fissa su impianti: un caso clinico. Rivista Italiana di Stomatologia (RIS) 2011(1):52-61.

OSTEOXENON®

References

24. L. Artese, D.A. Di Stefano, G. Iezzi, M. Piccirilli, S. Pagnutti, G. di Gregorio, V. Perrotti. Treatment of mandibular atrophy by an equine bone substitute: an immunohistochemical study in man Original Research Article. Italian Oral Surgery (2012). Epub ahead of print.

25. D.A. Di Stefano, M. Andreasi Bassi, M. Ludovichetti, S. Pagnutti Maxillary sinus lift with a collagenic equine heterologous bone substitute. Histomorphometric analysis. Original Research Article. Italian Oral Surgery (2011). Epub ahead of print.

26. Di Stefano DA, Cazzaniga A, Andreasi Bassi M, Ludovichetti M, Ammirabile G, Celletti R. The use of cortical heterologous sheets for sinus lift bone grafting: a modification of tulasne's technique with 7-year follow-up. Int J Immunopathol Pharmacol. 2013 Apr-Jun;26(2):549-56.

27. Pistilli R, Signorini L, Pisacane A, Lizio G, Felice P. Case of severe bone atrophy of the posterior maxilla rehabilitated with blocks of equine origin bone: histological results. Implant Dent. 2013 Feb;22(1):8-15

28. Santini S, Barbera P, Modena M, Schiavon R, Bonato M. Equine-derived bone substitutes in orthopedics and traumatology: authors' experience. Minerva Chir. 2011 Feb;66(1):63-72.

29. Di Stefano DA, Andreasi Bassi M, Cinci L, Pieri L, Ammirabile G. Treatment of a bone defect consequent to the removal of a periapical cyst with equine bone and equine membranes: clinical and histological outcome. Minerva Stomatol. 2012 Nov-Dec;61(11-12):477-90.

OSTEOXENON

OSTEOXENON

BIOTECK®

The science of bone tissue

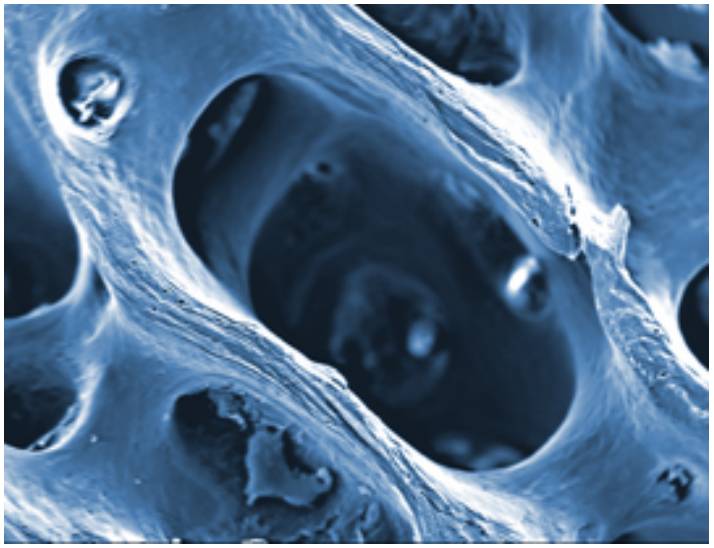



BIOTECK®

The science of bone tissue