Clinical Sheet

SOCKET PRESERVATION WITH THE AID OF A COLLAGEN MATRIX

Healing of the soft tissues by secondary intention may be promoted by using a three-dimensional collagen matrix.

Clinical case of Dr. Luca Lamazza
Private practitioner in Rome, Italy
luca.lamazza@gmail.com

The loss of a tooth, regardless of the cause, triggers a biological process that, over time, leads to the atrophy of the alveolar process. A condition is thus created that jeopardizes implant rehabilitation, from both an esthetic and a functional point of view; in the most severe cases, it prevents the placement of the implant.

Whenever placement of the implant following an extraction is delayed, especially when there is no possibility to plan when it may be performed, one should have recourse to ridge preservation techniques, namely grafting the post-extraction socket with a biomaterial the presence of which limits the development of the atrophy and, in any case, allows adequate bone tissue to regenerate for subsequent placement of the implant. Following the graft, the soft tissues can heal by primary or secondary intention, depending on the surgical technique used. Healing by primary intention requires preparation of an appropriate flap, an operation that requires certain skills on the part of the surgeon and prolongs the duration of the procedure.

La guarigione per seconda intenzione, d'altra parte, avviene in tempi più lunghi ed espone il paziente ad un maggiore rischio di infezione. Questo processo può essere favorito coprendo l'innesto osseo con una matrice tridimensionale collagenica che crea un substrato favorevole alla colonizzazione e quindi alla rigenerazione dei tessuti molli, contribuendo nel frattempo alla protezione dell'innesto stesso.

Materials

The procedure described in this sheet entails the use of an equine bone substitute in 0.5-1 mm cortical-cancellous granules (Bioteck), obtained by enzymatic removal of antigens using the exclusive Zymo-Teck process, and of a three-dimensional collagen matrix (Xenomatrix, Bioteck) consisting of an octagonal portion, approx. 10 x 20 mm, and a round patch measuring 14 mm in diameter. The placement of the matrix entails the detachment of a few millimeters of the periosteum all around the gingival margin of the socket. Following the graft of the biomaterial, one of the short sides of the octagonal portion of the matrix is inserted under the palatal or lingual side of the gingival margin.

The round patch is placed to protect the graft and is covered with the octagonal portion of the matrix, while the other three sides are tucked under the remaining gingival margins. A cross stitch stabilizes the margins and the two matrix portions.

Fig. 1 *– The irremediably compromised tooth 2.6.*

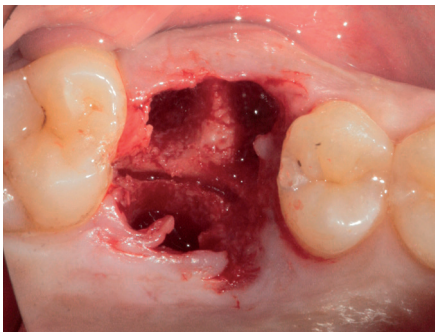

Fig. 2 *– The post-extraction socket before the graft.*

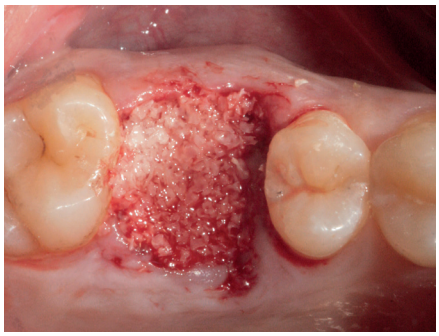

Fig. 3 *– Graft of the equine biomaterial.*



Fig. 4 *– The Xenomatrix three-dimensional collagen matrix. The two patches are linked by a septum that must be cut by the surgeon before their placement.*

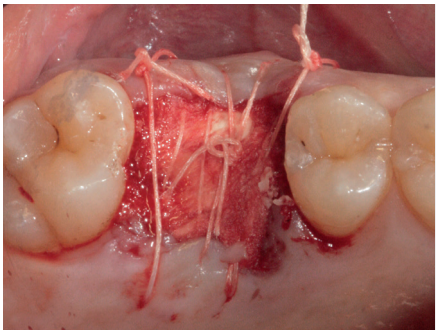

Fig. 5 *– The stitch stabilizes the entire reconstruction. The gingival margins are left to heal by secondary intention.*

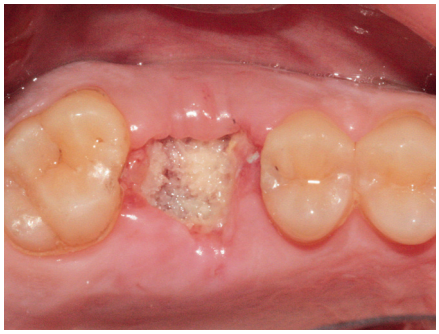

Fig. 6 *– Appearance of the soft tissues following the removal of the stitches, 7 days later.*

SOCKET PRESERVATION WITH THE AID OF A COLLAGEN MATRIX

Healing of the soft tissues by secondary intention may be promoted by using a three-dimensional collagen matrix.

Results

The sheet summarizes the case of a patient who underwent the extraction of a compromised tooth (2.6). The socket was preserved with the equine bone substitute graft and was subsequently protected with the three-dimensional collagen Xenomatrix. Following atraumatic extraction of the compromised tooth, the matrix was placed in accordance with its standard placement protocol, i.e. by placing a double layer of matrix on top of the graft. The particular form in which the matrix is supplied made it possible to easily tuck the octagonal portion underneath the gingival margins, after a few millimeters thereof had been partially detached all around the edge of the socket. The gingival margins and the collagen matrix were stabilized with a few stitches. No flap was lifted, therefore.

The stitches were removed 7 days later. The patient was followed up at 14, 28 and 42 days after the procedure and each month thereafter until the placement of the implant, which took place one year after the extraction surgery. The patient was temporarily rehabilitated 15 days later and, after another month, was fitted with the final prosthesis (a single crown).

From a clinical point of view, excellent healing by secondary intention was observed without any complications on the part of the soft tissues: no inflammation or infection process was observed. One year later, we found that the bone volume at the grafted socket had been optimally preserved. The patient is currently followed up at the author's practice.

The results of this case indicate that the use of the Xenomatrix three-dimensional collagen matrix in socket preservation procedures may promote healing by secondary intention, simultaneously acting as a barrier that prevents the colonization of the grafted socket by the soft tissues.

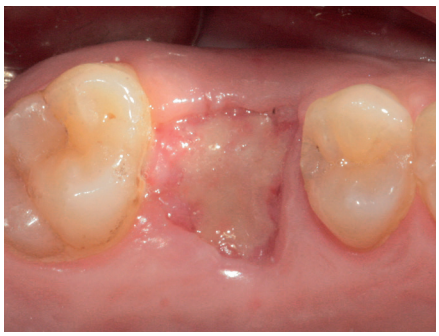

Fig. 7 *– Appearance of the soft tissues 14 days after the procedure. Conspicuous fibrinoid appearance.*

Fig. 8 *– The soft tissues 28 days after the procedure.*

Fig. 9 *– The soft tissues 42 days after the procedure.*

Fig. 10 *– The soft tissues at the 5-month follow-up. Full re-epithelialization of the soft socket tissue and formation of keratinized tissue through epithelial migration from the alveolar edges.*

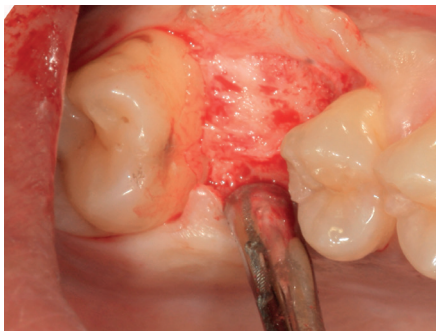

Fig. 11 *– When the site was reopened, one year after the regeneration surgery, the bone tissue appeared regenerated and preserved in terms of volume.*

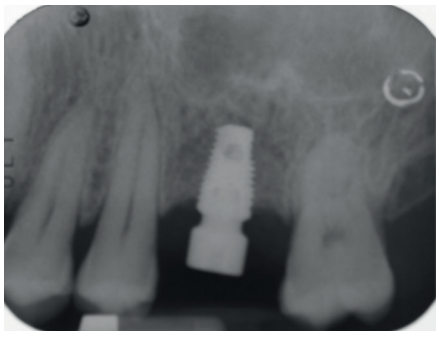

Fig. 12 *– The X-ray after implant placement confirms the preservation of the alveolar bone volume.*