Enzyme-Deantigenic Equine Bone and Anorganic Bovine Bone: Histomorphometric Comparison in Post-Extractive Socket Grafting

POSTER N° 13

DI STEFANO Danilo Alessio[1,2]*, ZANIOL Terry[3], DE BLASIO Leonardo Ilario Cesare[4], CINCI Lorenzo[5], PIERI Laura[6]

[1]*Private Practice, Milan, Italy*; [2]*Adjunct Professor, Dental School, Vita-Salute University and IRCCS San Raffaele, Milan, Italy*
[3]*Private Practice, Crocetta del Montello, Italy*
[4]*Universidad Europea de Madrid, Madrid, Spain*
[5]*Department of Neuroscience, Psychology, Drug Research and Child Health (Neurofarba), University of Florence, Florence, Italy*
[6]*Department of Health Sciences, Interdepartmental Forensic Medicine Section, University of Florence,Florence, Italy*

BACKGROUND

After tooth extraction, the socket may be grafted with a bone substitute according to the principles of socket preservation (1). Among natural grafts, anorganic bovine bone (Bio-Oss, Geistlich; ABB) is the xenograft with longest history of clinical use. An alternative xenograft is equine bone (Osteoxenon, Bioteck; EDEB) made non-antigenic using digestive enzymes. No literature data exist comparing the histomorphometric outcome of ABB and EDEB when used to graft post-extractive sockets.

AIM

The objective of this investigation was to retrospectively compare the histomorphometric data relating to bone samples collected from post-extractive sockets that had been grafted using EDEB or ABB.

CONCLUSIONS

The greater amount of NFB observed when EDEB was grafted may partially be explained by the different behavior of osteoclasts that was observed when they were cultured on the two materials in previous in vitro studies (2-3). This behavior may, in turn, be explained by the presence of native collagen in EDEB and its absence in ABB (4). EDEB, providing a greater amount of NFB at the moment of implant placement might facilitate implant osseointegration; yet ABB, showing a lower resorption rate than EDEB, could be more effective in preserving the bone volume of the grafted post-extractive sockets. Further comparative, prospective long-term studies should be carried out to address this matter.

BIBLIOGRAPHY

1. De Risi V, Clementini M, Vittorini G, Mannocci A, De Sanctis M. Alveolar ridge preservation techniques: a systematic review and meta-analysis of histological and histomorphometrical data. Clin Oral Implants Res 2015; 26:50-68.
2. Perrotti V, Nicholls BM, Horton MA, Piattelli A. Human osteoclast formation and activity on a xenogenous bone mineral. J Biomed Mater Res A 2009; 90:238-246.
3. Perrotti V, Nicholls BM, Piattelli A. Human osteoclast formation and activity on an equine spongy bone substitute. Clin Oral Implants Res 2009; 20:17-23.
4. Benke D, Olah A, Möhler H. Protein-chemical analysis of Bio-Oss bone substitute and evidence on its carbonate content. Biomaterials 2001; 22:1005-1012.

MATERIALS AND METHOD

Patients included in this retrospective study (1) underwent one or more atraumatic tooth extraction in the maxillae, (2) had no acutely infected sockets, (3) had sockets walls intact, (4) had their post-extractive sockets immediately grafted using either EDEB or ABB, (5) had delayed implant placement carried out between 4 and 6 months after grafting, and (6) had at least one biopsy specimen collected at the grafted site at the time of implant placement. Biopsies were processed and qualitatively and quantitatively analyzed separately by two histologists who were blind to the graft being used. Quantitative analysis included assessing the % of newly-formed bone (NFB) and of residual biomaterial (RB).

RESULTS

Records retrieved related to 46 patients, 25 men and 21 women with a mean age of 54 years (range 43 to 75). **Figures 1 and 2** show two representative cases (one treated with EDEB and one with ABB). The mean healing period of patients grafted using EDEB and ABB was 4.1 ± 1.2 and 4.4 ± 1.2 months, respectively. Histomorphometric results were NFB = 45.12% ± 10.54%; RB = 10.91% ± 4.27% (N=41 sockets) for EDEB, and NFB = 33.61% ± 9.71%; RB = 18.47% ± 5.62% (N=43 sockets) for ABB (**Figures 3,4**). The difference between the two groups was significant for both for NFB and RB. Healing occurred without complications and no signs of inflammation or cartilage-like tissue were observed.

Figure 1: A case where EDEB was used is shown. a) X-ray showing the initial patient status. Tooth 25 is fractured and compromised. **b**) The element after being extracted. **c**) The post-extractive socket before grafting. **d**) The socket after being grafted. **e**) A collagen membrane is placed below the gingival rims to cover the graft. **f**) A single cross stitch stabilizes the reconstruction. **g**) Appearance of the regenerated socket 4.1 months after the grafting surgery. **h**) A bone core is collected using a trephine bur. **i**) The bone sample after collection. **j**) An implant (Stone, 3.75 × 14 mm, IDI Evolution, Concorezzo, Italy) is placed into the regenerated bone. **k**) The final prosthetic rehabilitation. **l**) One-year control radiograph, peri-implant bone levels were mantained.

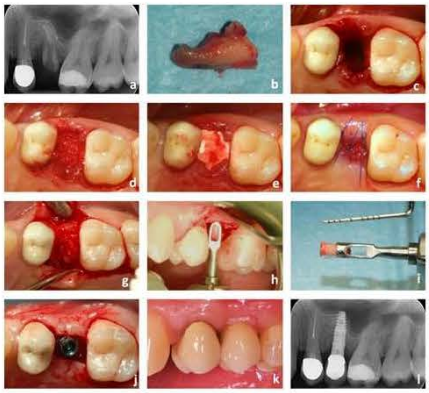

Figure 2: A case where ABB was used is shown. a) X-ray showing the initial patient status. Tooth 25 is fractured and compromised. **b-f**) As in Figure 1. **g**) Appearance of the regenerated socket 3 months after the grafting surgery. **h-k**) As in Figure 1. **l**) One-year control radiograph, showing maintenance of peri-implant bone levels.

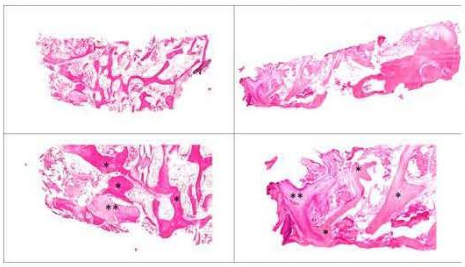

Figure 3: Hematoxylin-eosin staining, histology. Top: 3.5 × magnification. Bottom: detail, 10 × magnification. Left, an ABB case. Right, an EDEB case. Symbols: *, newly formed bone; **, residual biomaterial.

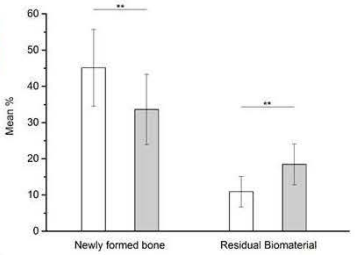

Figure 4: Histomorphometric analysis results. Difference between EDEB (white) and ABB (light gray) are significant for both NFB and RB at a p<.05 level of confidence (**).

WWW.IAO-ONLINE.COM
Poster Awards
1° CONGRESSO INTERNAZIONALE IAO
#MILANO2017
19, 20 e 21 ottobre

Clinical Research