Clinical Sheet

A CASE OF PERI-IMPLANTITITIS TREATED WITH A NEW GENERATION BONE PASTE

The residuals of definitive prosthetic cement can favor the development of peri-implantitis

Case of Dr. Giacomo Tarquini
Private practitioner in Rome, Italy
g_tarquini@libero.it

Among the causes that may lead to the onset of peri-implantitis there is also the presence of improperly removed residues of permanent prosthetic cement. This risk factor, in association with medium or high individual susceptibility to periodontal disease, may increase the likelihood of peri-implantitis. From the pathogenetic point of view, one observes the formation of peri-implant bone resorption due to tissue lysis triggered by the infectious and inflammatory process. When the implants involved are deemed viable and it is decided to maintain them, it is possible to intervene – depending on the morphology of the peri-implant defect – by means of a Guided Bone Regeneration procedure (GBR).

The surgical protocol requires the decontamination of the titanium surface, accurate debridement of the reactive tissue inside the peri-implant lesion and grafting a bone substitute associated with the placement of a barrier membrane, whose purpose is to prevent, by physically covering the defect, its colonization by unwanted cell types (epithelial cells and fibroblasts from connective tissue) enabling access and proliferation only to cells capable of regenerating the missing bone tissue with new tissue. The choice of fully remodeling biomaterials can enable the restoration of the natural bone component around the implant.

Materials

The bone substitute used in the case presented in this sheet is a bone paste with a moldable texture (Activabone Mouldable, Bioteck) obtained by mixing a resorbable polymer hydrogel added with Vitamin C (called Exur) with micro-granules of equine cancellous bone, collagen-preserved bone granules and demineralized bone matrix (DBM) of equine origin, produced by means of the exclusive enzymatic antigen elimination process Zymo-Teck. The particular consistency of this paste makes for easier application and eases homogeneous filling of bone defects. The osteoconduction provided by the bone granules is combined with the osteopromotive properties of DBM capable of speeding up bone regeneration. The bone paste has been protected with an equine pericardium membrane (Heart, Bioteck). The natural network of collagen fibers of this membrane allows it to withstand traction and, if required, to be fixed with suitable osteosynthesis means and/or sutures. Its protection time is 3-4 months.

Fig. 1 *– On clinical examination, a probing depth is observed which reaches 10-12 mm on the vestibular side.*

Fig. 2 *– Radiographically, a significant peri-implant resorption cone is observed.*

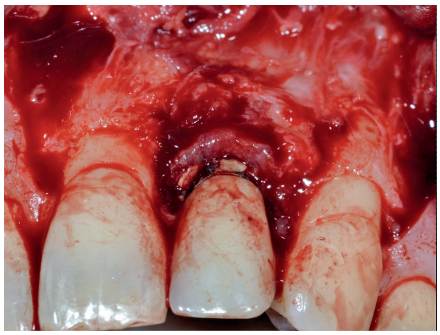

Fig. 3 *– Once a flap is elevated, one observes the presence of a considerable amount of reactive tissue and residues of permanent prosthetic cement.*

Fig. 4 *– Once the fibrous tissue is removed, the recipient cortical bone is repeatedly drilled using an insert mounted on an ultrasonic handpiece.*



Fig. 5 *– The Heart membrane is molded to adapt around the neck of the implant.*

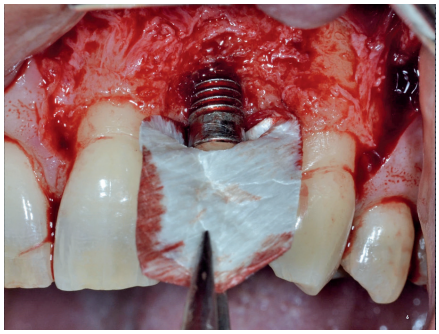

Fig. 6 *– The membrane is fixed palatally and already partially reflected around the implant.*

A CASE OF PERI-IMPLANTITITIS SOLVED THROUGH USE OF A NEW GENERATION BONE PASTE

The residues of permanent prosthetic cement may aid the onset of peri-implantitis in patients suffering from periodontal disease.

Results

The patient came to the surgeon's attention complaining of a painful swelling at a crown on the implant in 2.2. The radiographic and clinical examination confirmed the presence of a rather extensive peri-implantitis, with probing depths between 10 and 12 mm on the vestibular side and between 4 and 5 mm on the palatal side. There was also a fistula on the buccal side; the implant was in any case stable. After acquiring the patient's I.C. a treatment plan was scheduled, including decontamination of the implant surface and, at the same time, execution of a Guided Bone Regeneration (GBR) procedure in order to restore the correct crestal profiles. After taking the prescribed antibiotic prophylaxis, a full-thickness trapezoidal flap was elevated, extending from tooth 2.1 to tooth 2.3. Once the flap was elevated, one noted the presence of a considerable amount of reactive tissue and residues of permanent prosthetic cement, which were immediately removed.
The peri-implant surface was then decontaminated by means of a specific insert mounted on an ultrasonic handpiece exploiting the bactericidal effect of cavitation and a decontaminating gel was applied. The cortical bone was then repeatedly drilled using an appropriate insert mounted on the same ultrasonic handpiece, in order to foster the first angiogenic events following the graft.
Regenerative surgery was first performed by shaping the Heart membrane so that it could adapt to the implant neck. It was then palatally fixed and the bone defect was grafted with Activabone Mouldable. The defect was completely filled by applying a certain pressure with a blunt instrument. The membrane was then reflected on the vestibular side and permanently fixed with titanium pins. The suture was performed with PTFE 5-0 thread.
At the post-operative check-up, clinical examination showed excellent recovery of the soft tissue aesthetics. Peri-implant probing was within the range of 2-3 mm, on the buccal as well as palatal side. The radiographic examination shows a significant recovery of peri-implant bone levels.

Fig. 7 *– The Activabone bone paste is grafted by extruding it directly from the syringe.*

Fig. 8 *– When the paste is molded, it retains its shape.*

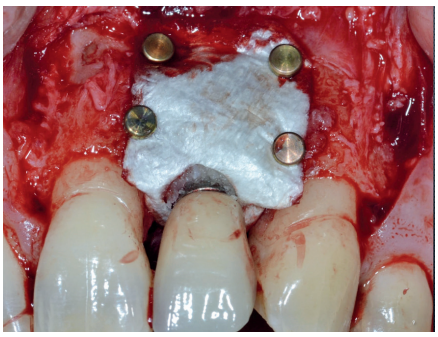

Fig. 9 *– The membrane is permanently reflected and fixed on the vestibular side with titanium pins.*

Fig. 10 *– The flap is sutured with a PTFE 5-0 thread.*

Fig. 11 *– At subsequent post-operative checks, optimal recovery of the soft tissue aesthetics is observed, with probing in the range of 2-3 mm.*

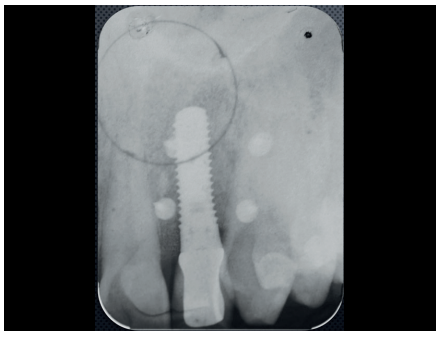

Fig. 12 *– The optimal recovery of peri-implant bone levels is also confirmed by the radiographic examination.*