Dentistry

Clinical Sheet

THREE-DIMENSIONAL REGENERATION BY ENZYMATICALLY DEANTIGENATED FLEXIBLE EQUINE BONE GRAFT

Volumetric restoration using Flex Cortical Sheet and heterologous collagen-preserved granules.

Clinical case of Dr. Angelo Comanzo
Private Practice in Ariano Irpino (Avellino), Italy
e-mail: angelo.comanzo@gmail.com

Following extraction of a tooth element, the alveolar process undergoes progressive resorption, which in the first 6 months after extraction can reach 3.8 mm in the vestibulo-palatal direction and 1.2 mm in the vertical direction[1]. This has dramatic consequences for subsequent implant surgery, as bone loss can make proper implant rehabilitation impossible[1]. This has led to the evolution of bone regeneration procedures aimed at halting or at least limiting the resorption process. Among these, guided bone regeneration (GBR) is the most widely used and predictable technique. Proper GBR follows the 4 principles[2] : 1) closure by first intention to limit the risks of infection, 2) respecting angiogenesis by promoting colonization of the site to be regenerated by blood vessels, 3) creating and maintaining a space for mesenchymal cell colonization, and 4) protecting the clot/graft material from soft tissue cell invasion and micromovements. In the regeneration of three-dimensional defects, reconstruction of a cortical bone layer that can preserve the correct aesthetic profile may be useful. Flexible cortical bone sheets can be used for this purpose, as they can be remodeled with the patient's own bone and at the same time can provide long-lasting protection to the graft, supporting the formation of new bone.

1Ten Heggeler et al. 2011 https://pubmed.ncbi.nlm.nih.gov/21091540/
2 Wang et al. 2006 https://www.ncbi.nlm.nih.gov/pubmed/16569956

Materials

Regeneration surgery was performed using a collagen-preserved cortical-cancellous granules bone graft of 0.25-1mm particle size (OsteOXenon, OSP-OX31, Bioteck Spa Spa) in combination with a flexible cortical bone sheet (Osteoplant-OsteOXenon Flex Cortical Sheet, OSP-OX08, Bioteck Spa). Both materials are equine-derived and are obtained through the unique Zymo-Teck enzymatic deantigenation process (Bioteck Spa), which, by selectively removing antigens at low temperatures, is able to preserve the mineral phase and bone collagen in their native conformation. This allows physiological recognition by cells involved in bone regeneration and complete remodeling with the patient's bone. The Flex Cortical Sheet undergoes an additional process of partial demineralization that makes it flexible once hydrated and it is therefore easily adaptable to curvilinear contours and surfaces. This bone sheet acts both as a long-protection time membrane (> 6 months) and cortical bone graft.

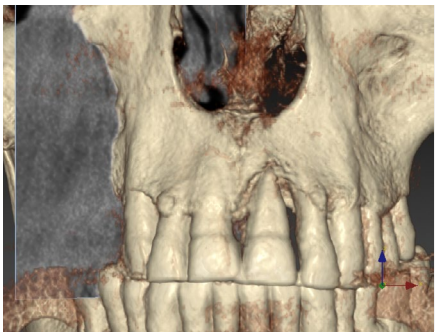

Fig. 1 *– Fig.1 Cone beam CT scan showing bone loss at the level of element 2.1.*

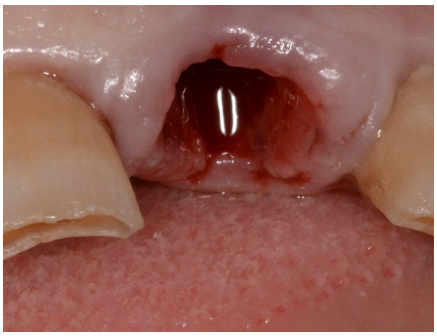

Fig. 2 *– Atraumatic tooth element extraction 2.1.*

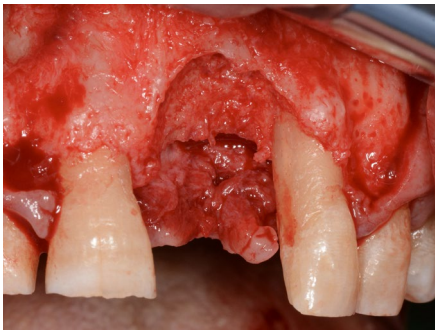

Fig. 3 *– Frontal view of the bony defect. Note the wide vestibular fenestration and bony deficiency in the vertical direction.*

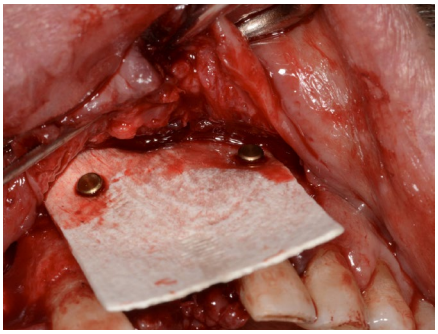

Fig. 4 *– The Flex Cortical Sheet is fixed vestibularly with two titanium pins and hydrated in situ with saline.*

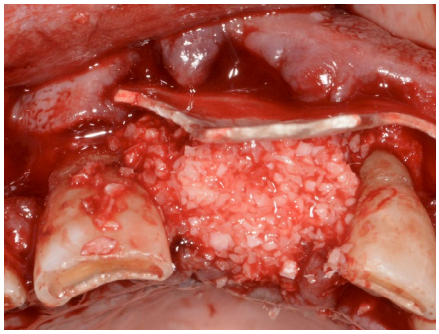

Fig. 5 *– After lamina contouring, the site was grafted with a mix of 50% autologous bone and 50% heterologous granules.*

THREE-DIMENSIONAL REGENERATION BY ENZYMATICALLY DEANTIGENATED FLEXIBLE EQUINE BONE GRAFT

Volumetric restoration using Flex Cortical Sheet and heterologous collagen-preserved granules.

Results

The clinical case involved a 70-year-old patient with severe grade mobility (grade 3) and oscillation of more than 3-4 mm of tooth element 2.1, accompanied by functional inability to chew. Analysis of the bone defect and evaluation of the patient's periodontal status were performed through OPT, endoral X-ray and maxillary upper jaw cone beam CT scan, which showed bone loss at the level of 2.1.

Thus, the removal of the compromised tooth element and vertical and horizontal bone regeneration using biomaterials and autologous bone was planned following appropriate medical and dental history assessment.

The procedure began with making the primary incisions necessary to delineate the flap, which was trapezoidal in shape.

Full-thickness debridement of the sculpted flap allowed for skeletonization of the maxilla and highlighting of the defect, followed by cleaning through sonic and ultrasonic scalers.

At this point, the still rigid Flex Cortical Sheet was appropriately positioned to avoid the apexes of adjacent teeth, secured buccally by 3.5-mm titanium pins, and then contoured.

Autologous bone was then harvested to obtain a 50% graft with collagen-preserved cortical-cancellous mix granules of equine origin that was compacted into the bone defect.

After imbibition with saline, a gradual curvature of the Flex Cortical Sheet was obtained and stabilized at the palatal side without additional fixation screws.

The open flap was sutured with 5/0 polyglycolic acid and an ozone-based antimicrobial gel was applied.

Suture removal after 15 days showed optimal tissue maintenance in the vertical direction. Follow-up by CT cone beam after six months showed 10-mm ridge augmentation. Clinical images confirmed abundant bone regeneration with excellent integration of the Flex Cortical Sheet.

With these favorable conditions, the second surgery was pursued to insert the implant fixture in the correct position relative to the patient's incisors.

At 11 months after GBR, the final prosthesis was delivered. Radiographic and clinical follow-ups at 18 months after GBR showed excellent volumetric maintenance.

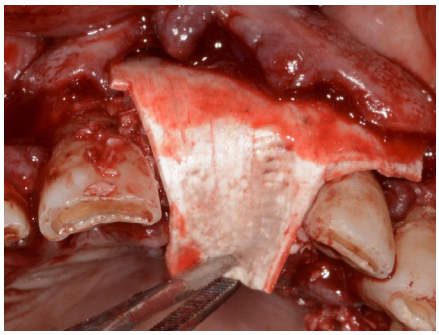

Fig. 6 *– The Flex Cortical Sheet is gradually curved until it fully covers the graft and is finally enveloped at the palatal level.*

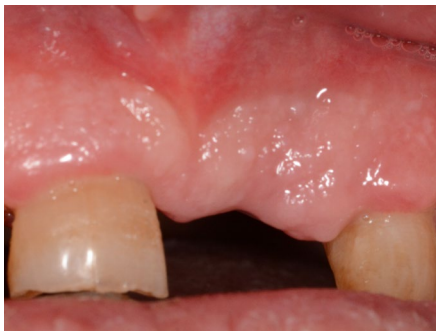

Fig. 7 *– Healing at 21 days. Note the excellent clinical appearance of the soft tissue*

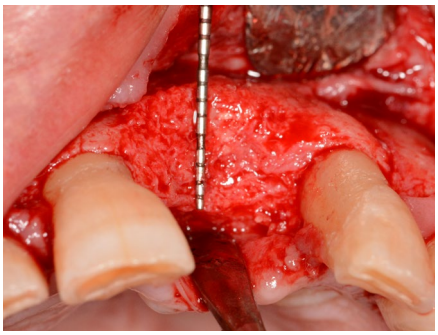

Fig. 8 *– Site reopening at 6 months (occlusal view): note the abundant volumetric increase horizontally and the integration of the Flex Cortical Sheet.*

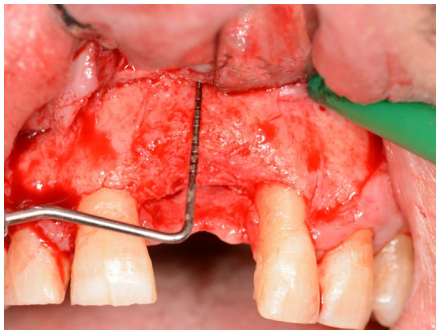

Fig. 9 *– Site reopening at 6 months (frontal view): excellent bone regeneration is appreciated vertically.*

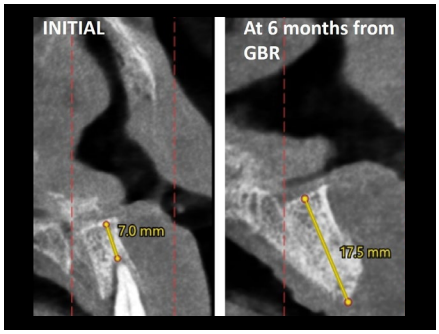

Fig. 10 *– CBCT analysis shows a vertical increase of 10 mm at 6 months after GBR.*

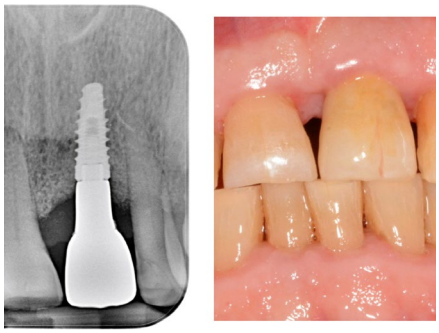

Fig. 11 *– Endoral X-ray and clinical appearance of prosthesis at 18 months after regeneration.*

Visit **www.bioteckacademy.com** for other clinical sheets and to access the ever up-to-date scientific literature.