

Horizontal onlay by using heterologous bone block and resorbable pericardium membrane in conjunction with a major sinus lift

Dr. Alberto Materni, Genoa – Dental technician Massimo Surpi, Genoa

CASE REPORT

Premise

Bone regeneration procedures make it possible to restore deficiencies in virtually all atrophic areas. Implant positioning to re-establish the masticatory load is thus made easier, with no functional and aesthetic impairments. The research of grafting biomaterials able to osteointegrate, maintain bone volume and reduce the many complications due to using autologous bone (*gold standard*) has steered regenerative surgery towards grafts that are conducive to excellent regeneration, so as to support proper implant positioning.

In this case report, a sinus lift and a horizontal maxillary *onlay* were performed by grafting collagen material of equine origin, made antigen-free with multi-enzyme treatment.

Purpose

The purpose of this paper was to position implants in a prosthetically guided manner, performing bone regeneration with heterologous material only: a sinus lift and a horizontal *onlay*. It was decided to graft a material of equine origin, made antigen-free by means of enzymes and to use a covering pericardium membrane, in order to evaluate inserting the implant in an appropriately regenerated bone area, without having recourse to intra- and extraoral harvesting.

Materials

An appropriately molded 10x20x5 mm block of cancellous bone (OSTEOXENON[®], Bioteck, Italy) was grafted on the vestibular side. The membranes used are in equine pericardium (HEART[®], Bioteck, Italy). Implants were positioned in the regenerated site (Straumann, Switzerland). Sutures were made in Goretex.

Methods

The 67-year-old patient with bone deficiency in the 2nd quadrant of about 5 mm in a vestibular-palate direction and of about 10 mm vertically (Photo 1), whose dental formula is missing 23, 24, 25, 26 (Photo 2) requires fixed type prosthetic rehabilitation to restore occlusion.

The patient is in good health and nothing is reported in medical history (ASA1).

In pre-surgical treatment the patient performed washes with Chlorhexidine 0.2% for 1 minute, and was also administered 2g Amoxicillin and Clavulanic Acid (Augumentin, GlaxoSmithKline, Italy) one hour before the surgery as antibiotic prophylaxis. The procedure was performed in local anesthesia with Articaine 1:100.000.

The preliminary X rays made it possible to plan the implant procedure. In view of the available space for inserting the implant and small thickness of the residual crest, it was decided to insert the implants in a single *step* at the same time as the sinus lift (Photo 4 and 5), while it was decided to perform a horizontal *onlay* in the crest to restore the defect and insert the implants at a later stage.

For the sinus lift, a crest incision was performed with release in the mesial area to the defect, for better soft tissue management. Complete detachment of the Schneiderian membrane was then performed up to the nasal wall and the particulate was inserted (OX Granules, Bioteck, Italy) and the first two implants (in zone 26 Tissue Level Wide Neck 4.8x10 mm and in zone 25 Tissue Level Regular Neck 4.1x10 mm, Straumann, Switzerland). The site was then prepared for horizontal regeneration. The existing bone was perforated with rose head burs of 0.8 mm diameter (Photo 3) and a block of equine bone made antigen-free enzymatically was placed, appro-

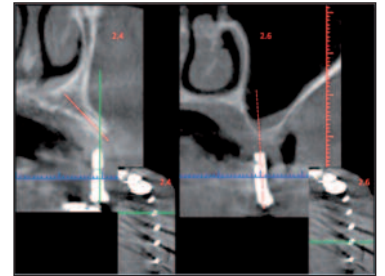


Photo 1

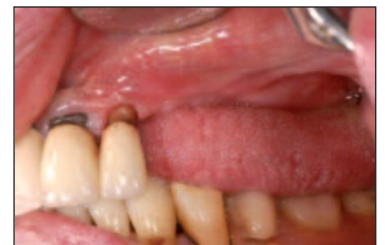

Photo 2

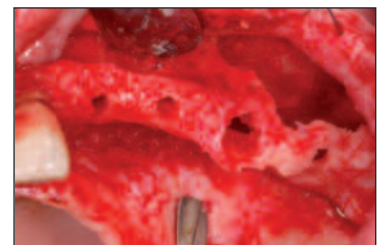


Photo 3

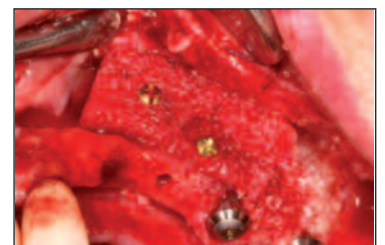

Photo 4

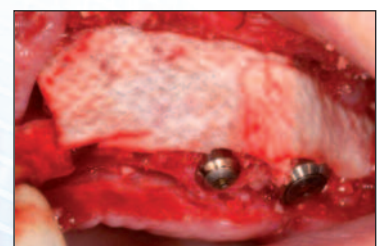

Photo 5

riately molded and fixed with two 8mm-long osteosynthesis screws (Photo 4). The graft was covered with 2 pericardium membranes that do not require using fixing screws owing to their adhesion properties (Photo 5). Suture was performed without tension and healing by primary intention was obtained.

Four months later the site was reopened and the screws were removed. The graft appeared **well vascularized: no resorption was observed, and the grafted volume was therefore retained**. In fact, it should be noted that the screw heads are flush with the graft (Photo 6).

To ascertain the quality of the graft, a biopsy was collected in the area where a fixing screw was, which was sent to the laboratory of reference for histological analysis.

Two more implants were then inserted (in zone 24 Tissue Level Regular Neck 4.1x10 mm and in zone 23 Bone Level Narrow Crossfit 3.3x10 mm Straumann, Switzerland) and immediate prosthesis application was then performed.

Three months later the final prosthetic teeth were positioned (Photo 8). The histological analysis showed that the biopsy core was **vital**, with gaps populated by osteocytes, the existing connective tissue was nourished by blood vessels and there was no cartilage tissue. The picture was compatible with the **direct ossification process in progress**. There were also some loose fragments of biomaterial intended for remodeling (Photo 9).

Conclusions

The need to reestablish functionality of an atrophied maxilla leads the dentist to considering implant positioning as being at risk owing to the extant bone defect. That is why one opts for intervening with bone regeneration using biomaterials, which prove to be able to meet volume and stability requirements and to assure results that are comparable to autologous bone grafts. The equine-origin heterologous biomaterial – made antigen-free with a multi-enzyme mixture, and used for both the sinus lift, in granules, and for the horizontal *onlay*, in block – has made it possible to position the required implants to assure the appropriate load and adequate stability, as well as a sufficient bone thickness around the implants to assure their long-term stability. Using a slow-resorption membrane to cover the graft has enabled physiological remodeling and protection from epithelial cell invasion, an effect that has been maintained for the length of the time required.

The correct orientation of the implants positioned was only possible thanks to the degree of bone regeneration obtained by grafting the biomaterial.

Bibliography

- 1) **Hämmerle C, Karring T.:** Guided bone regeneration at oral implant sites. *Periodontol* 2000 1998;17:151-175.
- 2) **Collins TA.:** Onlay bone grafting in combination with Branemark implants *Oral and maxillofacial surgery clinics of North America*. 1991;3:893-902.
- 3) **Cordaro L, Amade DS, Cordaro M.:** Clinical result of alveolar ridge augmentation with mandibular block bone grafts in partially edentulous patients prior to implant placement. 2002;13(1):103-11.
- 4) **D. Stievano, D. A. Di Stefano, M. Ludovichetti, S. Pagnutti, F. Gazzola, C. Boato, E. Stellini:** Maxillary sinus lift through heterologous bone grafts and simultaneous acid-etched implants placement. Five year follow-up. *Minerva Chirurgica*. 2008 63:79-91.

The prosthetic material (zirconium crowns in porcelain, all single) was manufactured by Massimo Surti.

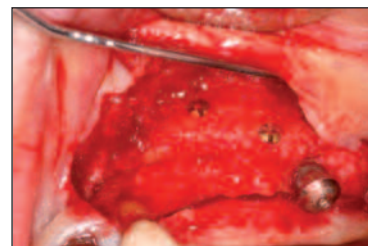


Photo 6

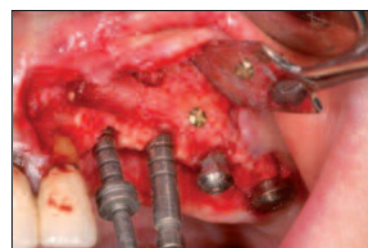

Photo 7

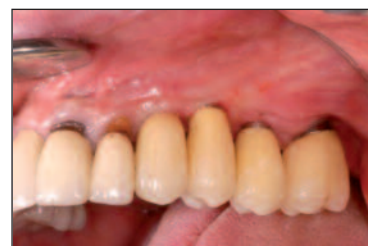

Photo 8

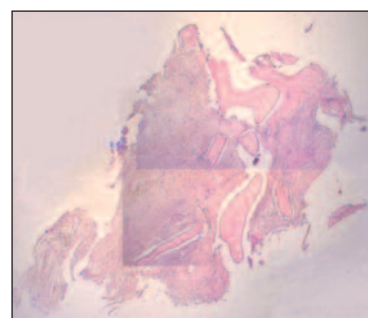


Photo 9

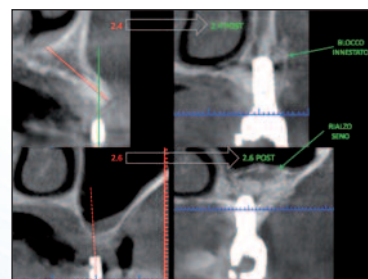


Photo 10

For more information contact:

Dr. Alberto Materni
Massimo Surpi
Dr. Stefano Pagnutti

E-mail: alberto.materni@fastwebnet.it
E-mail: surpimassimo@libero.it
E-mail: s.pagnutti@bioteck.com

Cell. +393407562640